

available at www.sciencedirect.comjournal homepage: www.elsevier.com/jbmt

PREVENTION & REHABILITATION: ORIGINAL RESEARCH

Visceral mobilization can lyse and prevent peritoneal adhesions in a rat model

Geoffrey M. Bove, DC, PhD ^{a,*}, Susan L. Chapelle, RMT ^b

^a University of New England College of Osteopathic Medicine, Department of Pharmacology, 11 Hills Beach Rd., Biddeford, ME 04046, United States

^b Squamish Therapeutic Massage, 108-41105 Tantalus Rd., Squamish, BC, Canada

Received 17 February 2011; received in revised form 23 February 2011; accepted 24 February 2011

KEYWORDS

Surgical complications;
Bowel obstruction;
Infertility;
Pain

Summary Objective: Peritoneal adhesions are almost ubiquitous following surgery. Peritoneal adhesions can lead to bowel obstruction, digestive problems, infertility, and pain, resulting in many hospital readmissions. Many approaches have been used to prevent or treat adhesions, but none offer reliable results. A method that consistently prevented or treated adhesions would benefit many patients. We hypothesized that an anatomically-based visceral mobilization, designed to promote normal mobility of the abdominal contents, could manually lyse and prevent surgically-induced adhesions.

Material and methods: Cecal and abdominal wall abrasion was used to induce adhesions in 3 groups of 10 rats (Control, Lysis, and Preventive). All rats were evaluated 7 days following surgery. On postoperative day 7, unsedated rats in the Lysis group were treated using visceral mobilization, consisting of digital palpation, efforts to manually lyse restrictions, and mobilization of their abdominal walls and viscera. This was followed by immediate post-mortem adhesion evaluation. The rats in the Preventive group were treated daily in a similar fashion, starting the day after surgery. Adhesions in the Control rats were evaluated 7 days after surgery without any visceral mobilization.

Results: The therapist could palpate adhesions between the cecum and other viscera or the abdominal wall. Adhesion severity and number of adhesions were significantly lower in the Preventive group compared to other groups. In the Lysis and Preventive groups there were clear signs of disrupted adhesions.

Conclusions: These initial observations support visceral mobilization may have a role in the prevention and treatment of post-operative adhesions.

© 2011 Elsevier Ltd. All rights reserved.

* Corresponding author. Tel.: +1 207 602 2921; fax: +1 207 602 5931.
E-mail address: gbove@une.edu (G.M. Bove).

Introduction

Peritoneal adhesions have been reported as an adverse side effect of surgery for more than a century (Hertzler, 1919), and occur in 90–100% of cases following surgery (Menzies and Ellis, 1990; Stanciu and Menzies, 2007). They are a leading cause of bowel obstruction, infertility, pelvic pain, and repeated surgeries (Almeida and Val-Gallas, 1997; Attard and MacLean, 2007; Beck et al., 1999; Menzies and Ellis, 1990; Parker et al., 2007; Stanciu and Menzies, 2007). Adhesions are pathological bands of fibrous connective tissue that occur between abdominal or pelvic organs and other structures, including viscera and the abdominal wall. One report indicated that >5% of all hospital readmissions following abdominal or pelvic surgery are due to adhesions (Ellis et al., 1999). The most recent estimate of the economic burden of morbidity associated with abdominal adhesions is \$5 billion, in the United States alone (Wiseman, 2008). Post-surgical peritoneal adhesions are a significant public health concern.

Adhesions form following a number of injuries to the peritoneum, including mechanical trauma, drying, blood clotting, and foreign object implantation (Ryan et al., 1971). The inflammation caused by peritoneal trauma from any etiology leads to a disruption of the balance between the fibrin-forming and fibrin-dissolving capacities of the peritoneum, favoring the deposition of a fibrin-rich exudate on the damaged area (diZerega and Campeau, 2001; Reed et al., 2008). If the fibrin is not resolved by the fibrinolytic system within days, adhesions form (Holmdahl, 1997). Persistent adhesions can prevent the normal sliding of the viscera during peristalsis and movements of the body, such as respiration. Adhesions become both innervated and vascularized (Herrick et al., 2000; Sulaiman et al., 2000).

Adhesiolysis (surgical lysis of persistent and symptomatic peritoneal adhesions) is a common procedure (Szomstein et al., 2006), but often leads to reformation and new adhesions (Diamond et al., 1987; Diamond and DeCherney, 1987; Gutt et al., 2004; Milingos et al., 2000). Prevention is a far more desirable goal (Gomel et al., 1996; Mettler, 2003; Scott-Coombes et al., 1993), and much effort has been expended on adhesion prevention using various chemical compounds and barriers (Corrales et al., 2008; Guo et al., 2009; Ilbay et al., 2004; Kutlay et al., 2004; Mettler et al., 2003; Oncel et al., 2004). Systematic reviews of these treatments have reported that none consistently prevent adhesion formation (Kumar et al., 2009; Metwally et al., 2006). Identifying an effective preventive measure, or a treatment that avoids recurrence, has the potential to avoid much morbidity and economic burden.

Textbooks have been written describing techniques of visceral manipulation and include the treatment of post-operative scar tissue and adhesions (Barral, 2007; Finet, 2000). Clinicians from various backgrounds who practice these methods anecdotally report the ability to palpate and lyse adhesions, and that pain and other symptoms, including amenorrhea, infertility, and digestive problems, are resolved following treatment. Such claims have never been systematically investigated. Other than a case series and editorial from 1899 (Coe, 1899; Haberman, 1899), there

are no clinical or basic science investigations related to the efficacy or possible mechanisms of such treatments.

We designed the current study to evaluate the hypothesis that visceral mobilization, currently in clinical use by one of the authors (SLC) and applied to a well-characterized rat model (Ar'Rajab et al., 1991; Irkorucu et al., 2009), can lyse established adhesions, and can prevent peritoneal adhesions from forming. In this initial report, we show that it is possible to identify, treat, and prevent experimentally induced visceral adhesions. These observations open a line of investigation with the potential to benefit those who suffer adverse effects due to peritoneal adhesions.

Methods

Animals and surgery

All procedures were consistent with the Guide for the Care and Use of Laboratory Animals (National Research Council, USA), and were approved by the University of New England Institutional Animal Care and Use Committee. Thirty adult, male Long Evans rats were obtained from Charles River Laboratories (USA), and weighed 300 g when used. The methods were designed following previously published reports (Ar'Rajab et al., 1991; Irkorucu et al., 2009). Rats were anesthetized with isoflurane in pure oxygen (4% for induction, 1.8–2% for maintenance), and their abdominal walls were shaved and scrubbed with betadine and 70% isopropanol. The surgical field was draped and a 2 cm vertical incision was made 3–4 mm lateral and to the right of the linea alba, approximately 1/3 below and 2/3 above the umbilicus. The cecum was identified, exteriorized using atraumatic forceps, and grasped with gloved fingers. A sterile toothbrush with a 13 mm circular head (Braun, USA) was stroked 10–12 times across the anterior and posterior cecal surfaces, causing multiple petechial hemorrhages over a combined area of approximately 7 cm². The cecum was placed back in the abdominal cavity. The toothbrush was then inserted into the abdominal cavity and the anterior parietal peritoneum was abraded using 5 back and forth strokes per side. The incision was closed in layers, using 3 sutures for the abdominal wall and 3 sutures for the skin (4-0 Monoweb; Webster Veterinary, USA), and the rat was allowed to recover.

Experimental design

Rats were assigned to 1 of 3 groups: Control, Lysis, or Preventive. All underwent the cecal abrasion surgery described above. Control and Lysis rats were allowed to survive 7 days, during which time no procedures were performed. Control rats were killed on postoperative day 7 without performing any other treatment, using an overdose of sodium pentobarbital (200 mg/kg, i.p.) and their adhesions evaluated (see below). Lysis rats were palpated and treated by one of the authors (SLC) on postoperative day 7 as described below. Following this treatment, the rats were killed and their adhesions were immediately evaluated. Preventive group rats were palpated and treated each day following surgery, after which they were killed and their adhesions were evaluated.

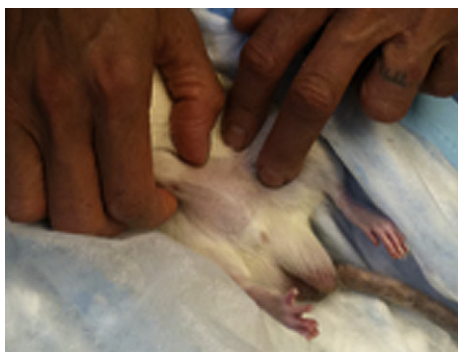

Figure 1 Representative image of palpation and treatment method in an unsedated rat. The anterior abdominal wall is being lifted, and light pressure is being applied to the cecum. Note that the limbs appear relaxed.

Palpation and treatment

All treatments were performed on unsedated and unrestrained rats. Rats in the Lysis and Preventive groups were placed on their side (Figure 1), and their abdomens palpated using scaled-down methods that are practiced upon humans. As in humans, treatments were tailored to the palpation findings. When the examiner perceived adhesions between the cecum and another structure, one side of the palpated adhesion was stabilized using one finger while the other side was mobilized away from the restriction using a finger from the other hand, feeling for reduction in stiffness. Each evaluation and treatment session lasted 5–10 min per rat. Rats in the Preventive group were examined and treated daily, starting with the first postoperative day. The treatment was designed to

prevent the formation of adhesions by maintaining normal movements. With these rats, the examiner lifted the abdominal wall from the underlying organs and felt for restriction of movement. The viscera were palpated and the quality of movement assessed. The cecum was gently mobilized medially to laterally, as well as anterior to posterior. The inferior portion of the cecum was stabilized while stretching the upper portion away. The small intestine was gently mobilized. Rats in the Lysis group were examined and treated once for approximately 5 min. When adhesions were perceived using the methods described above, attempts were made to lyse them. Lytic treatments were extensions of the methods that were used in the Preventive rats. For cecal to abdominal wall adhesions, the abdominal wall was pinched into a fold over the adhesion, forcing the cecum away from the abdominal wall. When such an adhesion was released, the cecum dropped inferior in the abdomen and was no longer palpable. If a restriction was partially released, it was difficult to stabilize the cecum in order to release the remaining restriction. In these cases it was easily determined by subsequent palpation that the restriction was not completely lysed. For other adhesions, one part of the cecum was stabilized or anchored and surrounding structures pushed away from this stabilized point. Following treatment, the abdominal contents were mobilized as detailed above.

Adhesion evaluation

Deeply anesthetized rats were perfused transcardially with buffered saline. The abdominal cavities were opened using wide inverted “U” incisions that extended from the lower margin of the thorax to the inguinal ligaments. The abdominal walls were slowly retracted inferiorly under

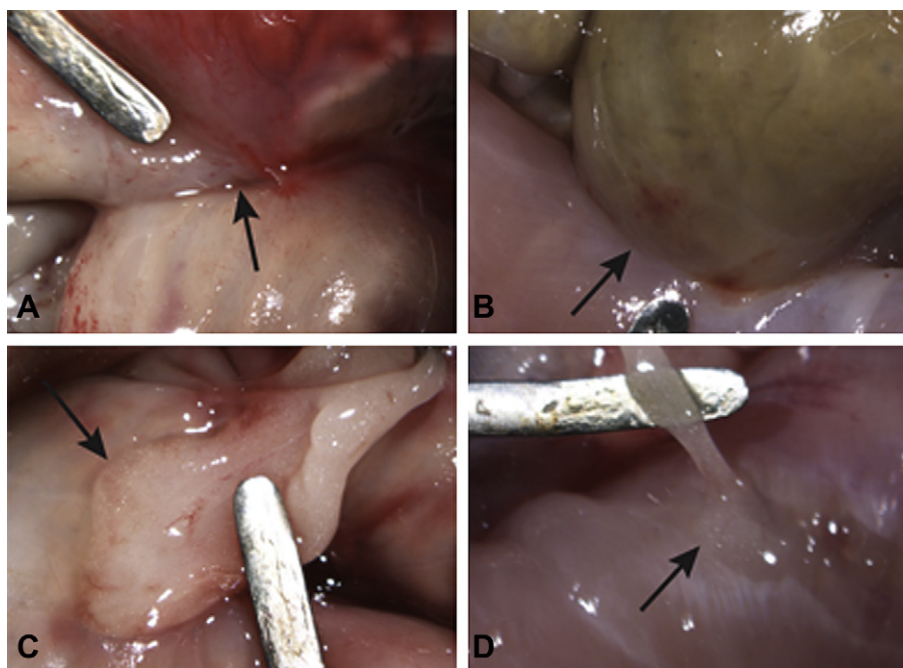


Figure 2 Representative images of the 4 types of adhesions (arrows). A. Cecum–cecum. B. Cecum–abdominal wall. C. Fat–cecum. 4. Fat–abdominal wall. Width of metal probe in all images = 2 mm.

observation with a surgical microscope to prevent avulsing adhesions. Adhesions were isolated and then photographed through the microscope using a digital camera (Nikon, USA).

Adhesion severity was graded on a scale of 0 (no adhesions) to 4 (established adhesions) following published protocols (Ar'Rajab et al., 1991; Irkorucu et al., 2009; Mazuji and Fadhli, 1965). Images were randomly assigned a number by an assistant not otherwise participating in the study, to blind the group assignments. Grading was performed by 2 investigators who were familiarized with the grading scheme using images taken from a group of rats not included in this study. The evaluating investigators viewed the images together, discussed their impressions until a consensus was reached, and assigned a single score.

Results

All 30 rats recovered from the surgery with no complications. The 20 rats in the Lysis and Preventive groups tolerated the palpation and treatment procedures well (Figure 1). These rats readily relaxed their overall movements and abdominal walls, facilitating the investigator to perform deep palpation, evaluation, and treatment of the abdominal contents.

During the post-mortem dissection, 4 types of adhesions were found: cecum–cecum, cecum–abdominal wall, cecum–fat, and fat–abdominal wall (Figure 2 and Table 1, "fat" refers to testicular fat pad). The number of rats with adhesions did not differ by group (Fisher's Exact Test). The number of adhesions was significantly lower in the Preventive group ($p < 0.05$, Fisher's Exact Test). In the Lysis group, there was clear evidence of 6 broken adhesions (Figure 3 and Table 1). In the Preventive group, there was evidence of 4 adhesions that had been disrupted and healed. The one cecum–cecum adhesion in this group showed no overt evidence of inflammation, and this adhesion was very easily disrupted with the fingers. In this group, adhesion remnants were evidenced by shallow peritoneal defects that did not appear inflamed (Figure 3D), as compared to the acutely lysed adhesions (Figure 3A–C).

To visually demonstrate an adhesion and the effect of manual lysis, a small fiber optic camera (SeeSnake, RIDGID Tools, USA) was inserted into the abdomen of an anesthetized rat with a palpable cecum to abdominal wall adhesion (part of a further study). A small midline incision was made below the xiphoid and the 9 mm diameter camera head was inserted. The abdominal wall was gently inflated to

view the adhesion (Figure 4A), which appeared similar to a previously published image of a post-myomectomy adhesion (Lau and Tulandi, 2000). The abdomen was deflated, and the fingers were then used from outside the abdomen to lyse the adhesion. Figure 4B shows the impact of the first attempt, which left two small, filmy adhesions. On the second attempt, these were lysed, and the cecum dropped below the colon and out of sight of the camera.

Analysis of variance of the adhesion scores revealed a significant treatment affect ($p < 0.01$, Table 1). Post-hoc tests (Tukey's HSD) showed that the largest difference was between the Prevention group [mean = 0.6 ± 0.97 (SD)] and the Lysis group (mean = 1.9 ± 1.84 ; $p < 0.01$).

Petechial hemorrhages induced by the surgical intervention remained after 1 week in all groups. While not quantified, there were fewer remaining lesions on the ceca in the Preventive group (such as in Figure 2B). There was better overall healing of the parietal peritoneal incision site in this group.

The palpation and treatment skills used on humans were readily transferrable to the rats. The ceca were easily identified using palpation through the abdominal wall, and restricted cecum–cecum and cecum–abdominal wall adhesions could be appreciated. In rats with adhesions, the abdominal contents felt more viscous than in rats with no adhesions, where the abdomen felt fluid and mobile. Where the cecum was attached to the abdominal wall there was a distinctly abnormal resistance to movement ("end feel") that indicated the presence of an adhesion. Adhesions involving fat were difficult to palpate, and this was thought to be because they caused no appreciable restriction in mobility. In the Lysis group, identified cecum–cecum and cecum–abdominal wall adhesions offered resistance to initial lysis, but were easily torn once started. The force of the treatments did not evoke escape behavior (flinching, biting). Lysing an adhesion took between 15 s and 2 min, depending on the position and perceived severity. In the Preventive group, there was noticeably decreased overall mobility of the viscera after 1 day of surgery (compared to normal rats). However, mobility was better at all evaluations compared to the Control. The developing adhesions in the Preventive group rats were more easily lysed, suggesting that they were less established. Cecum-abdominal wall adhesions were perceived by palpation in 7 of these rats at post-surgical day 3, and were broken using much less force. At day 7, no cecum–abdominal wall adhesions were noted by palpation, and this was shown to be accurate by post-mortem evaluation.

Table 1 Adhesion severity scores, total number of adhesions per group, and numbers of different types of adhesions.

Group	Severity	Adhesed	Total	Cec–Cec	Cec–Abd	Cec–Fat	Fat–Abd
Control	1.4 (1.35)	7/10	8	0	1	6	1
Lysis	1.9 (1.84)	7/10	9 (6)	2 (2)	1 (4)	2	3
Preventive	0.6 (0.97)*	3/10	3** (4)	1 (1)	0 (3)	2	0

ANOVA of severity scores showed significant treatment affect ($p < 0.01$), with the main difference being between the Preventive and Lysis groups ($*p < 0.01$, Tukey's HSD). Total number of adhesions per group was significantly lower in the Preventive group ($**p < 0.05$, Fishers Exact Test). Numbers in parentheses are identified broken adhesions. Cec = cecum, Abd = internal abdominal wall, Fat = testicular fat pad.

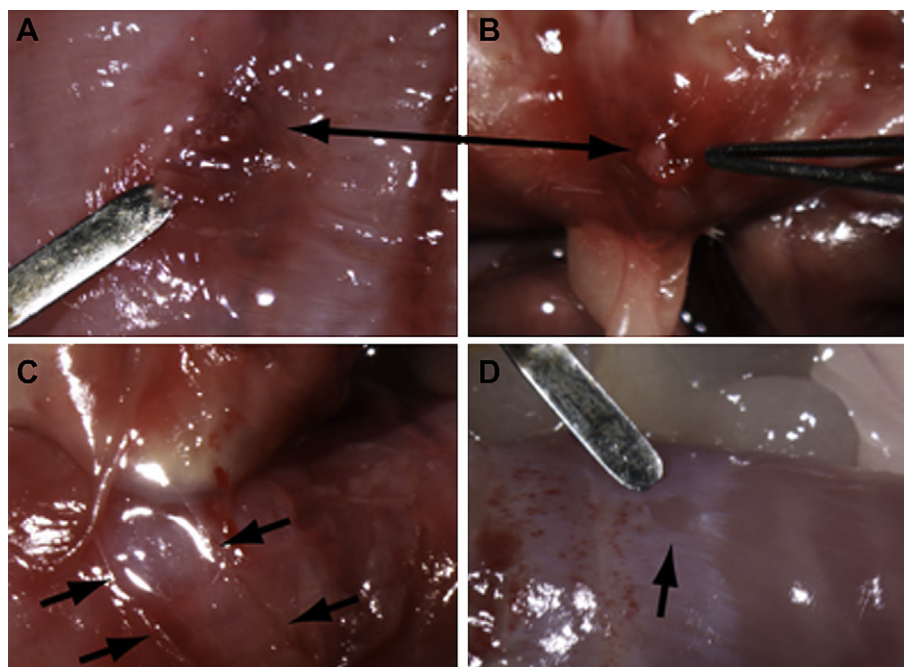


Figure 3 A and B. The arrows point to the two sides of an acutely avulsed adhesion from the same rat. No other signs of adhesions were present in this animal, other than the intact fat–cecum adhesion that can be seen below the avulsed stump in B. C. This large cecum–abdominal wall adhesion was partially lysed by the treatment. The therapist indicated prior to dissection that the adhesion was only partially lysed, and that the remaining adhesion was too deep to stabilize for treatment. The arrows indicate the margins of the previously ovoid and macular adhesion. The cecum remained partially adhered to the abdominal wall, and was subsequently relatively easily lysed in entirety during necropsy. D. Small peritoneal defect from a rat in the Prevention group, not seen in other animals, and taken as evidence of a previously lysed but poorly established adhesion. Metal probe width in C = 2 mm, applies to all images.

Discussion

Movements between organs and the abdominal wall are necessary to accommodate peristalsis and the highly varying volume of the intestines. Following surgery, adhesions form that can limit these movements, causing pain and other pathology. Here we show in a rat model that visceral mobilization designed to promote mobility between the organs can acutely lyse adhesions, and more importantly can prevent adhesions from forming. These findings provide an initial scientific justification for the use of visceral mobilization for the treatment and prevention of peritoneal adhesions.

We hypothesized that by manually assisting free movement of the bowel following injury, fewer adhesions would form, and this was reflected in the results. Although the experiment was not designed to determine which part of the adhesion process was disrupted, the process did not proceed to fibrosis in as many cases. It is likely that the repeated disruption of fibrin bridges did not allow fibroblast invasion required for the formation of adhesions (Raftery, 1981). Since surgery induces ischemia and inhibition of fibrinolytic processes (Buckman et al., 1976; Raftery, 1981) it also seems likely that the mobilization encouraged fibrinolysis through increased fluid movement and thus metabolite exchange in the peritoneum.

Our data also demonstrate that it is possible to manually lyse post-surgical adhesions in a rat model, and this is

consistent with the clinical practice of our therapist (SLC). The procedures used were similar in design and timing as for humans, on a smaller scale and in general with less force. Just as for surgical lysis, these adhesions may reform (Milingos et al., 2000; Tittel et al., 2001), since the process that initiated the adhesions may have been re-initiated. Our combined data suggest that if either surgical or manual lytic treatments are followed by mobilization, the adhesions may not reform. Such questions can be answered through further experimentation using this model.

We hypothesize that stasis is a key element in the development of postoperative adhesions. It is known that surgery leads to temporary ileus (Kalff et al., 1998; Mattei and Rombeau, 2006; Turler et al., 2002), which has been implicated in the formation of adhesions (Springall and Spitz, 1989). There is limited support that post-surgical abdominal massage reduces surgically-induced ileus (Habertlin, 1899; Le Blanc-Louvry et al., 2002). However, mobilization of the viscera is expected to reduce stasis, and this may be why adhesions did not form as often in our preventive group. Since the first few days following surgery seem to be critical for adhesion formation (diZerega and Campeau, 2001; Orita et al., 1991), early intervention, and thus prevention, is likely to be most effective.

Although surgeries in 6 rats prior to this study led to a 100% adhesion rate, our experimental control group had 3 rats with no adhesions. This was likely due to the surgical methods. In the pilot studies, we made 3–4 cm incisions,

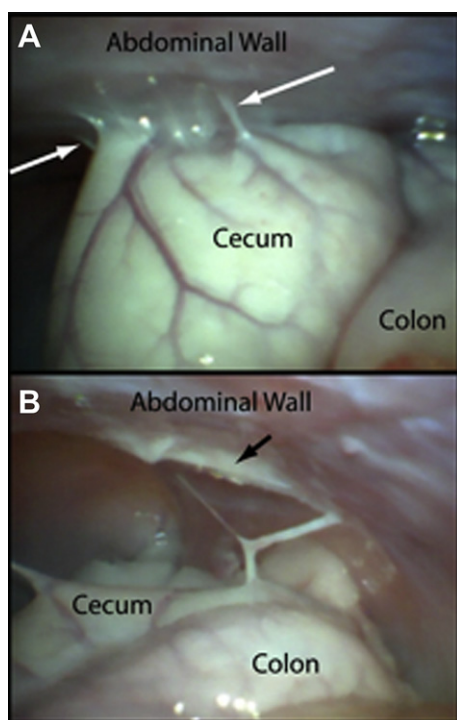


Figure 4 A. A post-surgical abdominal adhesion between the cecum and abdominal wall is shown between white arrows. B. Appearance of same area, following manual lysis. Note that the cecum has dropped behind the colon. Black arrow indicates a remnant of the adhesion.

but in the present experiment, the incisions were 2 cm. The surgeries typically took less than 5 min prior to closure of the abdominal wall, and there were no post-surgical complications (infections, wound dehiscence) in any of the rats. These factors likely contributed to lower baseline adhesion numbers and scores than in similar studies (Irkorucu et al., 2009), and therefore there was less room to observe changes in the 2 groups that underwent intervention. These observations have a clinical correlate; laparoscopic surgery involves much smaller (~1 cm) incisions compared to open laparotomy (~10–15 cm incisions), and leads to fewer adhesions (Gutt et al., 2004; Majewski, 2005; Mettler, 2003). The extent of abdominal trauma seems positively correlated to the severity of subsequent adhesions, and our data support that limiting surgical exposure is important to limiting post-operative adhesion severity.

Abdominal massage has been part of medicinal cultures for centuries. Over 100 years ago, abdominal massage was promoted as an effective treatment to prevent adhesions and reduce post-operative ileus (Haberlin, 1899). There is precedence to support that abdominal massage is well tolerated immediately following surgery (Le Blanc-Louvy et al., 2002). If further experiments confirm and extend our initial findings, visceral mobilization could readily be implemented into post-surgical care and patient education. It is possible that visceral mobilization could become an economic and effective way of preventing and treating abdominal adhesions.

References

- Ar'Rajab, A., Ahren, B., Rozga, J., Bengmark, S., 1991. Phosphatidylcholine prevents postoperative peritoneal adhesions: an experimental study in the rat. *Journal of Surgical Research* 50, 212–215.
- Almeida Jr., O.D., Val-Gallas, J.M., 1997. Conscious pain mapping. *Journal of the American Association of Gynecologic Laparoscopists* 4, 587–590.
- Attard, J.A., MacLean, A.R., 2007. Adhesive small bowel obstruction: epidemiology, biology and prevention. *Canadian Journal of Surgery* 50, 291–300.
- Barral, J.P., 2007. *Visceral Manipulation II*. Eastland Press Inc., Seattle, WA.
- Beck, D.E., Opelka, F.G., Bailey, H.R., Rauh, S.M., Pashos, C.L., 1999. Incidence of small-bowel obstruction and adhesiolysis after open colorectal and general surgery. *Diseases of the Colon and Rectum* 42, 241–248.
- Buckman, R.F., Woods, M., Sargent, L., Gervin, A.S., 1976. A unifying pathogenetic mechanism in the etiology of intraperitoneal adhesions. *Journal of Surgical Research* 20, 1–5.
- Coe, H.C., 1899. Massage in the treatment of post-operative ileus. *The American Journal of the Medical Sciences* 117, 240.
- Corrales, F., Corrales, M., Schirmer, C.C., 2008. Preventing intraperitoneal adhesions with vitamin E and sodium hyaluronate/carboxymethylcellulose: a comparative study in rats. *Acta Cirurgica Brasileira* 23, 36–41.
- diZerega, G.S., Campeau, J.D., 2001. Peritoneal repair and post-surgical adhesion formation. *Human Reproduction Update* 7, 547–555.
- Diamond, M.P., DeCherney, A.H., 1987. Pathogenesis of adhesion formation/reformation: application to reproductive pelvic surgery. *Microsurgery* 8, 103–107.
- Diamond, M.P., Daniell, J.F., Feste, J., Surrey, M.W., McLaughlin, D.S., Friedman, S., Vaughn, W.K., Martin, D.C., 1987. Adhesion reformation and de novo adhesion formation after reproductive pelvic surgery. *Fertility and Sterility* 47, 864–866.
- Ellis, H., Moran, B.J., Thompson, J.N., Parker, M.C., Wilson, M.S., Menzies, D., McGuire, A., Lower, A.M., Hawthorn, R.J., O'Brien, F., Buchan, S., Crowe, A.M., 1999. Adhesion-related hospital readmissions after abdominal and pelvic surgery: a retrospective cohort study. *Lancet* 353, 1476–1480.
- Finet, G., 2000. *Treating Visceral Dysfunction: An Osteopathic Approach to Understanding and Treating the Abdominal Organs*. Stillness Press, Portland, OR.
- Gomel, V., Urman, B., Gurgan, T., 1996. Pathophysiology of adhesion formation and strategies for prevention. *Journal of Reproductive Medicine* 41, 35–41.
- Guo, H., Leung, J.C., Cheung, J.S., Chan, L.Y., Wu, E.X., Lai, K.N., 2009. Non-viral Smad7 gene delivery and attenuation of post-operative peritoneal adhesion in an experimental model. *British Journal of Surgery* 96, 1323–1335.
- Gutt, C.N., Oniu, T., Schemmer, P., Mehrabi, A., Buchler, M.W., 2004. Fewer adhesions induced by laparoscopic surgery? *Surgical Endoscopy* 18, 898–906.
- Haberlin, H., 1899. Die massage bei postoperativem ileus. *Centralblatt für Gynäkologie* 42, 1164–1167.
- Herrick, S.E., Mutsaers, S.E., Ozua, P., Sulaiman, H., Omer, A., Boulos, P., Foster, M.L., Laurent, G.J., 2000. Human peritoneal adhesions are highly cellular, innervated, and vascularized. *Journal of Pathology* 192, 67–72.
- Hertzler, A.E., 1919. *The Peritoneum*. Mosby, St. Louis.
- Holmdahl, L., 1997. The role of fibrinolysis in adhesion formation. *European Journal of Surgery - Supplements*, 24–31.
- Ilbay, K., Etus, V., Yildiz, K., Ilbay, G., Ceylan, S., 2004. Topical application of mitomycin C prevents epineural scar formation in rats. *Neurosurgical Review*.

- Irkorucu, O., Ferahkose, Z., Memis, L., Ekinci, O., Akin, M., 2009. Reduction of postsurgical adhesions in a rat model: a comparative study. *Clinics (Sao Paulo)* 64, 143–148.
- Kalff, J.C., Schraut, W.H., Simmons, R.L., Bauer, A.J., 1998. Surgical manipulation of the gut elicits an intestinal muscularis inflammatory response resulting in postsurgical ileus. *Annals of Surgery* 228, 652–663.
- Kumar, S., Wong, P.F., Leaper, D.J., 2009. Intra-peritoneal prophylactic agents for preventing adhesions and adhesive intestinal obstruction after non-gynaecological abdominal surgery. *Cochrane Database of Systematic Reviews* CD005080.
- Kutlay, J., Ozer, Y., Isik, B., Kargici, H., 2004. Comparative effectiveness of several agents for preventing postoperative adhesions. *World Journal of Surgery* 28, 662–665.
- Lau, S., Tulandi, T., 2000. Myomectomy and adhesion formation. In: diZerega, G.S. (Ed.), *Peritoneal Surgery*. Springer-Verlag, New York.
- Le Blanc-Louvry, I., Costaglioli, B., Boulon, C., Leroi, A.M., Ducrotte, P., 2002. Does mechanical massage of the abdominal wall after colectomy reduce postoperative pain and shorten the duration of ileus? Results of a randomized study. *Journal of Gastrointestinal Surgery* 6, 43–49.
- Majewski, W.D., 2005. Long-term outcome, adhesions, and quality of life after laparoscopic and open surgical therapies for acute abdomen: follow-up of a prospective trial. *Surgical Endoscopy* 19, 81–90.
- Mattei, P., Rombeau, J.L., 2006. Review of the pathophysiology and management of postoperative ileus. *World Journal of Surgery* 30, 1382–1391.
- Mazuji, M.K., Fadhli, H.A., 1965. Peritoneal adhesions; prevention with povidone and dextran 75. *Archives of Surgery* 91, 872–874.
- Menzies, D., Ellis, H., 1990. Intestinal obstruction from adhesions—how big is the problem? *Annals of The Royal College of Surgeons of England* 72, 60–63.
- Mettler, L., 2003. Pelvic adhesions: laparoscopic approach. *Annals of the New York Academy of Science* 997, 255–268.
- Mettler, L., Audebert, A., Lehmann-Willenbrock, E., Schive, K., Jacobs, V.R., 2003. Prospective clinical trial of spraygel as a barrier to adhesion formation: an interim analysis. *Journal of the American Association of Gynecologic Laparoscopists* 10, 339–344.
- Metwally, M., Watson, A., Lilford, R., Vandekerckhove, P., 2006. Fluid and pharmacological agents for adhesion prevention after gynaecological surgery. *Cochrane Database of Systematic Reviews* CD001298.
- Milingos, S., Kallipolitis, G., Loutradis, D., Liapi, A., Mavrommatis, K., Drakakis, P., Tourikis, J., Creatsas, G., Michalakis, S., 2000. Adhesions: laparoscopic surgery versus laparotomy. *Annals of the New York Academy of Science* 900, 272–285.
- Oncel, M., Remzi, F.H., Senagore, A.J., Connor, J.T., Fazio, V.W., 2004. Application of Adcon-P or Seprafilm in consecutive laparotomies using a murine model. *American Journal of Surgery* 187, 304–308.
- Orita, H., Fukasawa, M., Girgis, W., diZerega, G.S., 1991. Inhibition of postsurgical adhesions in a standardized rabbit model: intraperitoneal treatment with tissue plasminogen activator. *International Journal of Fertility* 36, 172–177.
- Parker, M.C., Wilson, M.S., van, G.H., Moran, B.J., Jeekel, J., Duron, J.J., Menzies, D., Wexner, S.D., Ellis, H., 2007. Adhesions and colorectal surgery - call for action. *Colorectal Disease* 9, 66–72.
- Rafferty, A.T., 1981. Effect of peritoneal trauma on peritoneal fibrinolytic activity and intraperitoneal adhesion formation. An experimental study in the rat. *European Surgical Research* 13, 397–401.
- Reed, K.L., Stucchi, A.F., Becker, J.M., 2008. Pharmacologic inhibition of adhesion formation and peritoneal tissue-type plasminogen activator activity. *Seminars in Reproductive Medicine* 26, 331–340.
- Ryan, G.B., Grobety, J., Majno, G., 1971. Postoperative peritoneal adhesions. A study of the mechanisms. *American Journal of Pathology* 65, 117–148.
- Scott-Coombes, D.M., Vipond, M.N., Thompson, J.N., 1993. General surgeons' attitudes to the treatment and prevention of abdominal adhesions. *Annals of The Royal College of Surgeons of England* 75, 123–128.
- Springall, R.G., Spitz, L., 1989. The prevention of post-operative adhesions using a gastrointestinal prokinetic agent. *Journal of Pediatric Surgery* 24, 530–533.
- Stanciu, D., Menzies, D., 2007. The magnitude of adhesion-related problems. *Colorectal Disease* 9, 35–38.
- Sulaiman, H., Gabella, G., Davis, C., Mutsaers, S.E., Boulos, P., Laurent, G.J., Herrick, S.E., 2000. Growth of nerve fibres into murine peritoneal adhesions. *The Journal of Pathology* 192, 396–403.
- Szomstein, S., Lo, M.E., Simpfendorfer, C., Zundel, N., Rosenthal, R.J., 2006. Laparoscopic lysis of adhesions. *World Journal of Surgery* 30, 535–540.
- Tittel, A., Treutner, K.H., Titkova, S., Ottinger, A., Schumpelick, V., 2001. Comparison of adhesion reformation after laparoscopic and conventional adhesiolysis in an animal model. *Langenbeck's Archives of Surgery* 386, 141–145.
- Turler, A., Moore, B.A., Pezzone, M.A., Overhaus, M., Kalff, J.C., Bauer, A.J., 2002. Colonic postoperative inflammatory ileus in the rat. *Annals of Surgery* 236, 56–66.
- Wiseman, D.M., 2008. Disorders of adhesions or adhesion-related disorder: monolithic entities or part of something bigger—CAPPS? *Seminars in Reproductive Medicine* 26, 356–368.